

# Wounds UK

---

An evaluation of the efficacy of Cutimed<sup>®</sup> Sorbact<sup>®</sup>  
in different types of non-healing wounds

*Sylvie Hampton*

---

# An evaluation of the efficacy of Cutimed® Sorbact® in different types of non-healing wounds

An increase in the availability of antimicrobial dressings has led to the overuse of these products, particularly those containing silver. This has raised concerns over the development of bacterial resistance and cost-effectiveness. The Cutimed® Sorbact® range of dressings has a unique mode of antimicrobial action, which effectively removes microbes from the wound bed. An evaluation of the product range was carried out in 21 patients with non-healing wounds. Findings suggest that Cutimed Sorbact is a suitable alternative to other available antimicrobials such as silver but without the issues of cost and bacterial resistance.

Sylvie Hampton

## KEY WORDS

Clinical-effectiveness  
Cost-effectiveness  
Antimicrobial  
Bioburden management  
Cutimed® Sorbact®

Over the past 30 years clinicians have been exposed to a wide and exciting range of wound care products and wound healing science has progressed significantly over this period (Queen et al, 2004). There is now an increased availability of antimicrobial dressings and those containing silver in particular are over used. Concerns associated with the overuse of silver and the consequent emergence of bacterial resistance are now being raised (Brett, 2005). Other concerns about its use have centred on issues such as toxicity, clinical efficacy and cost-effectiveness and need to be addressed (Cutting et al, 2007). Silver-containing products are more expensive than other equally effective dressings, so if they are used inappropriately this greatly adds to the cost of treatment (Tomaselli and Doughty, 2006).

## Cutimed® Sorbact®

The Cutimed® Sorbact® range (formally known as Cutisorb® Sorbact®) consists of dressings with antimicrobial abilities, but has none of the cost and bacterial resistance issues that can occur with antimicrobial products, particularly those containing silver. The range has been used globally for many years to dress infected and critically colonised wounds (Dahlerup, 1989; Meberg and Schøyen, 1990) and has a unique mode of action which effectively removes microbes from the wound bed that otherwise may result in delayed wound healing.

## Unique mode of action

It is now recognised that both aerobic and anaerobic microorganisms have the ability to degrade or damage host tissue at a wound site, through the production of a variety of enzymes and toxins (Jones et al, 2004). These same microorganisms are largely hydrophobic in nature. The Cutimed Sorbact dressings are coated with DACC (dialkyl carbamoyl chloride), a fatty acid derivative which makes the dressing highly hydrophobic. Once in physical contact with the wound bed, and in the presence of moisture, such as wound exudate, bacteria are hydrophobically attracted away from the wound by DACC and become bound to the dressing, thus reducing the overall concentration of microbes in the wound. This unique mode of action means Cutimed Sorbact is a useful dressing for reducing bacterial loads

and can be viewed as an alternative to silver; iodine, chlorhexidine, PHMB and any other antimicrobials.

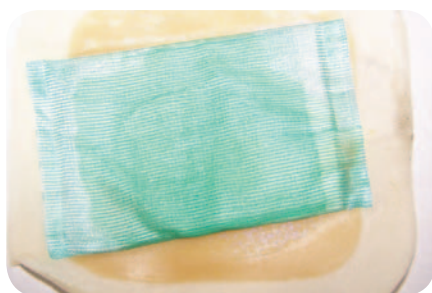Unlike with silver, there is no risk of bacterial resistance, wound discolouration and/or skin staining or release of toxins into the wound bed when using Cutimed Sorbact. There are also no limitations on the patients who can wear the dressings. However, the product must only be applied to a moist wound as this allows the micro-organisms to bind to the dressing and to prevent it from potentially adhering to the wound bed. This moisture can either be clinically introduced via an amorphous hydrogel on the wound bed, or is naturally present through wound exudate. In addition, there should be no presence of creams or ointments containing fatty substances as these could impair the effectiveness of the hydrophobic interaction.

## Product range

Cutimed Sorbact is available in a range of formats (Table 1); a cotton ribbon, a dressing pad which has a coated acetate wound contact layer and a highly absorbent core of non-woven viscose for exudate management (Figure 1) and an acetate swab. The swabs are available in a folded flat sheet format or a 3D tupper, suitable for packing wounds.

This article will now describe the findings of an evaluation of the Cutimed

Sylvie Hampton is Tissue Viability Consultant, Tissue Viability Consultancy Services Ltd, Eastbourne



**Figure 1. Cutimed Sorbact pad held in place by a hydrocolloid. Cutimed Sorbact can be used under any dressing or bandage as long as there is no other fatty substance present, such as cream or ointment.**

Sorbact dressing range carried out on 21 patients with several different types of non-healing wounds, and a selection of case reports from the study will be presented.

### Patient evaluation programme

#### Aims

The main aim of this patient evaluation programme was to determine the ability of the Cutimed Sorbact range to reduce the signs of increased bacterial load (indicated by inflammation, high levels of exudate and malodour) and promote healing in many different types of non-healing wounds.

#### Patient and wound profiles

Twenty one patients participated in the evaluation (m=7; f=14). The mean age was 83 years (range = 67–96 years). All wounds included in the evaluation were considered non-healing; that is, no signs of healing had been identified for at least three months before treatment with Cutimed Sorbact. Clinical infection was an exclusion criteria.

The patients either self-referred (n=3) to their local clinic or were residents in residential nursing or care homes (n=18) with their nurses seeking assistance on the patient's behalf. Each patient signed a consent form and was provided with a full explanation of what could be expected from using the dressing. If the patient was unlikely to understand fully what was being asked of them, their closest relative was involved in obtaining consent.

All wounds were reviewed over a period of at least four weeks. If the wound was healing but had not reached the stage of closure by week 4, then treatment with Cutimed Sorbact was continued for a period of up to 10 weeks.

Cutimed Sorbact was used on several different wound types including:

- ▶▶ Pressure ulcers (n=7)
- ▶▶ Mixed arterial and venous ulcers (n=5)
- ▶▶ Venous leg ulcers (n=4)
- ▶▶ Sinus wounds (n=2)
- ▶▶ Arterial leg ulcer (n=1)
- ▶▶ Surgical wound (n=1)
- ▶▶ Trauma wound (n=1).

#### Methodology

Wounds were assessed on inclusion into the evaluation and every week for the remaining four weeks for signs of malodour and exudate reduction. This was subjectively assessed by the tissue viability nurse. Progression towards healing was judged by the colour of the tissue types present in the wound according to the Wound Healing Continuum (Gray et

al, 2004) and a reduction in wound size. Wound size was measured by taking length and breadth measurement and calculating the surface area. Wound pH was tested in 14 patients who gave their permission to undertake a litmus test. Pain was assessed weekly in all patients using a visual analogue scale of one to 10 (10 being the worst pain that could be experienced) adapted from McCaffery and Beebe (1989).

Photographs were taken weekly with each wound assessed and dressed by the tissue viability nurse at each visit. Dressings were changed as often as required and, between visits, the dressings were changed by either the nurse who was caring for the patient, or the patient would visit the appropriate clinic. The use of secondary dressings and fixation devices, e.g. foam or hydrocolloid dressings, retention bandages or tapes that had been previously used, continued as before (Figure 1).

### Results

#### Wound healing

Over the 4 weeks of Cutimed Sorbact use:

- ▶▶ Six wounds healed
- ▶▶ Fourteen wounds were progressing towards healing with granulation or epithelial tissue present
- ▶▶ One wound had little change.

As all of the wounds were considered non-healing before the application of Cutimed Sorbact, these results give an indication of how wound status shifted along the Wound Healing Continuum towards granulation and epithelialisation during treatment (Figure 2). Those patients who progressed towards healing during the evaluation were provided with Cutimed Sorbact following the study to ensure progress continued.

#### Malodour

Malodour was identified in 56% of the wounds on day one with 28% of wounds being recorded as extremely malodourous and 28% as having some malodour. A reduction in odour from 56% to 0% at the end of the four-week evaluation was reported (Figure 3).

#### Effect on exudate levels and the peri-wound area

Bacteria in a wound increases exudate production (Edwards, 2001) by causing

**Table 1**

#### The Cutimed Sorbact product range

Product	Sizes*	Description
Cutimed Sorbact Pad	7cm x 9cm 10cmx10cm 10cmx20cm	Dressing pads made of DACC impregnated acetate and an absorbent core from polyester/viscose. Used as a primary dressing for moderately to heavily exuding wounds
Cutimed Sorbact Swab	4cm x 6cm* 7cmx9cm*	Swabs made of DACC impregnated acetate. Primary wound dressing for surface or deep wounds with any level of exudate
Round swabs (Tupfers)	3cm	Made of DACC impregnated acetate. Used for cleansing and packing deep wounds
Cutimed Sorbact Ribbon	2cmx50cm* 5cmx200cm*	As above, ribbon gauze made of DACC impregnated cotton for use in deep or cavity wounds, e.g. fistulas or abscesses

\*size of the product when folded

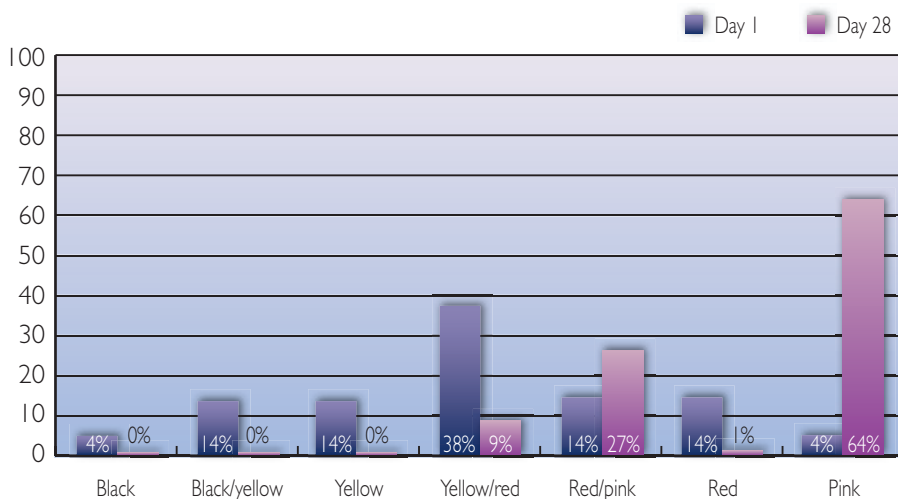


Figure 2. The wounds' progress towards healing can be seen by % colour change from day one to day 28.

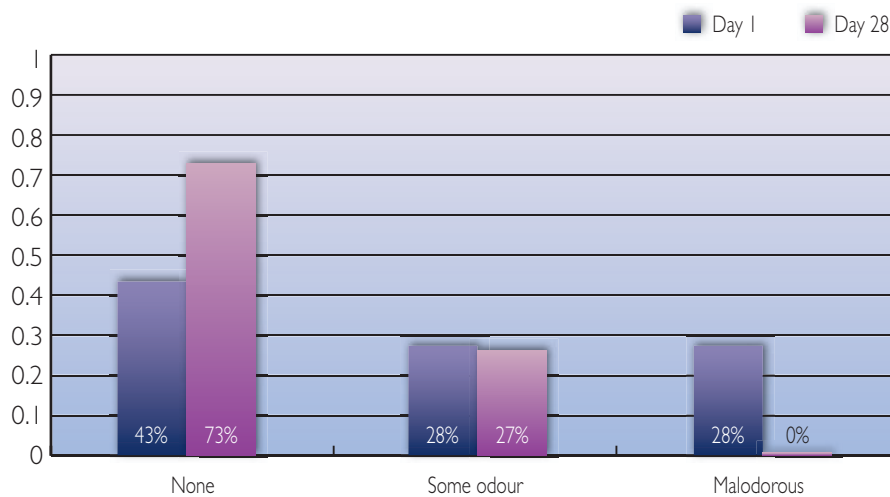


Figure 3. Reduction in odour can be seen from the shift between day one and day 28 from malodorous to some odour and from some odour to none.

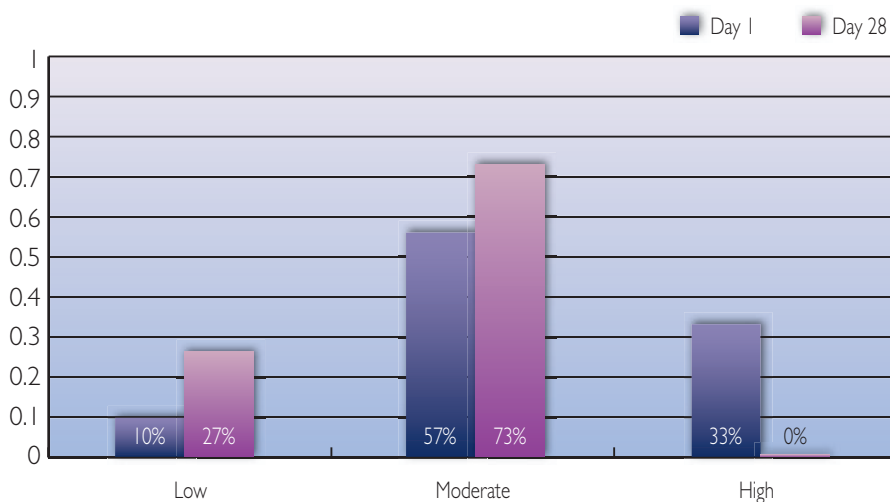


Figure 4. Demonstrates how the exudate levels reduced from high to moderate and from moderate to low between day one and day 28.

vasopermeability (Hampton and Collins, 2003). At the same time, proteases can damage the peri-wound area, causing

pain and weeping skin. The use of an antibacterial dressing such as Cutimed Sorbact can help reduce exudate levels

and, as a result, may reduce protease production. During the evaluation, improvements in the patients' peri-wound skin condition was observed with 38% of patients having healthy skin on day one increasing to 68% on day 28.

The Cutimed Sorbact absorbent pads absorbed exudate very well and did not 'reflect' exudate back on to the wound. Exudate levels were reduced in all patients (Figure 4). This reduction in exudate meant that dressing change intervals were also reduced from three dressing changes per week (on average) to one or two dressings per week (on average), making the dressing increasingly cost-effective.

*Effect on wound pain*

Cutimed Sorbact is not a dressing that could be expected to reduce wound pain. Flanagan (1997) described how a dressing needs to be moist in order to accomplish this. However, pain scale scores were significantly reduced during the evaluation (Figure 5). This decrease in pain could possibly be related to a reduction in both wound bioburden and reduced inflammation. Cutimed Sorbact stayed in place over the wounds between dressing changes and was easily removed without any trauma. Keeping the wound bed moist prevented any risk of the dressing sticking to the patient.

*Effect on pH*

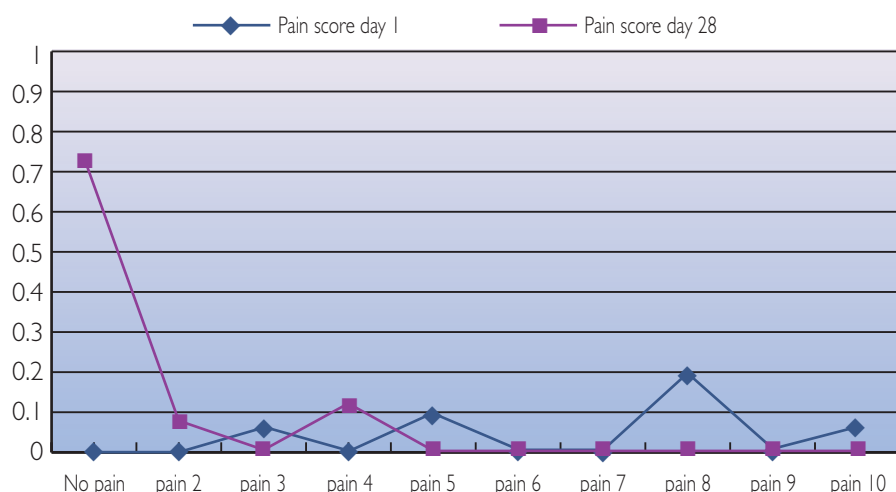
Research has demonstrated that an acidic environment of pH 6 is more conducive to healing (Wilson et al, 1979) with proteolytic activity greatest at a pH of 8.4 (Prager, 1999).

Fourteen patients agreed to the pH of their wounds being measured using a litmus strip. Results showed that pH was lowered to below 7.4 in 9 out of the 14 wounds (64%), resulting in a more acidic environment conducive to healing. In all the wounds tested, pH ranged from 7.2–8.4.

**Case studies**

*Treatment of a painful leg ulcer*

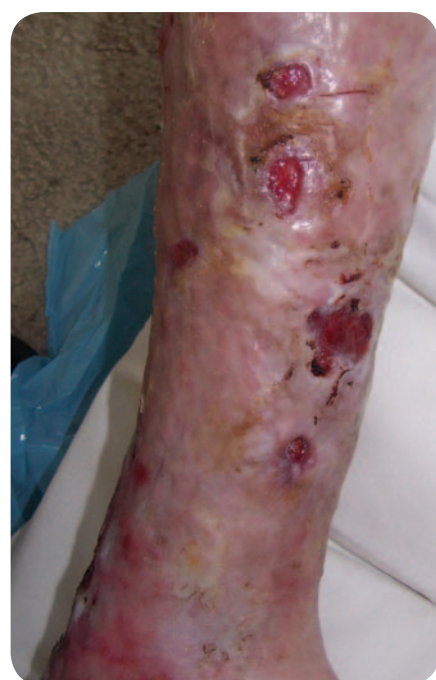Patient A was a 71-year-old male who had developed leg ulcers on the lateral left calf five years previously which had not healed (Figure 6). He required an operation to relieve an arterial blockage but was told his



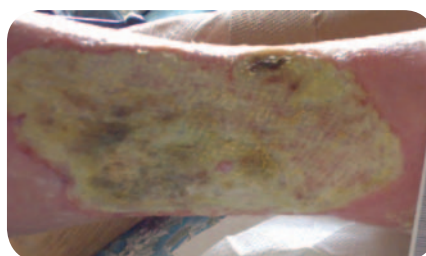
**Figure 5.** Pain on day one versus day 28. A visual analogue scale was used with 0 being no pain and 10 being the worst pain imaginable.



**Figure 6.** The sloughy, malodorous wound at presentation.



**Figure 7.** One month after applying Cutimed Sorbact.



**Figure 8.** This leg ulcer of three year's duration had 100% thick slough covering the wound bed.

leg wounds needed to heal first. His pain was regularly described as 10 on the visual analogue scale and he slept little at night as a result. He required physiotherapy, but again, treatment had been withheld until his wound healed. Patient A was walking on the side of his foot to relieve the pain and this had caused his ankle to become fixed. His nutrition was fair and his BMI was within normal limits.

Patient A was cared for by his practice nurse who was disheartened by the lack of progress in the wound, and also by the limitations of the wound dressings available from her local formulary.

On presentation, the wounds were multiple and extremely malodorous. The wound bed consisted of a mixture of red tissue and yellow slough. Measuring the wounds was difficult because of the different areas that were broken and the poor condition of the skin.

A Cutimed Sorbact swab (10 x 20cm) was applied to the lateral left leg and held in place by large surgical pads,

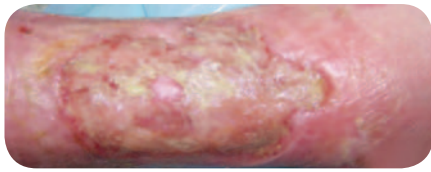
orthopaedic wool and a K-lite bandage. The first dressing change was made two days later. The change in granulation tissue was immediately apparent; the largest wound had epithelialised by 10% and a lower wound was 50% healed. All the wounds were greatly reduced in size. Within a week, Patient A no longer had pain (recorded as a 0 on the pain scale). After two weeks, large areas of epithelial tissue were visible and one of his major wounds had reduced in size by 50%. Within four weeks, the largest wound had become three smaller wounds with excellent granulation tissue present in the wound beds and epithelial tissue forming large bridges between the wounds (Figure 7). The lowest wound had healed completely and the middle wound had good granulation tissue present. Exudate levels reduced to the point that primary dressings could be changed three times per week, with no leakage or strikethrough occurring on the secondary dressings. The reduction in pain improved the patient's quality of life and this, coupled with his wound's progression towards healing, enabled him to visit the physiotherapist for manipulation of, and exercises for, his ankle.

#### Treatment of a three-year-old venous leg ulcer

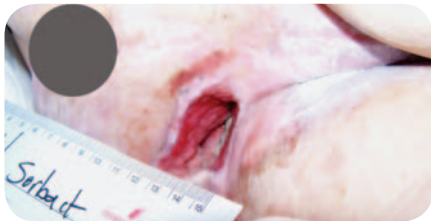Patient B was a 92-year-old female with cancer of the breast and bowel with multiple secondary tumours. Eating was difficult for her and as a result she had a BMI of 19 which placed her in a category of slightly below normal weight.

Patient B had suffered with a right lateral leg ulcer for three years (Figure 8). The wound measured 14 x 6.5cm, and was covered with malodorous, thick yellow slough. The wound was considered to have an increased bioburden but was not clinically infected. Patient B also recorded her pain experience as an 8 on the visual analogue scale. Previously, a series of dressings, including Acticoat (Smith and Nephew Healthcare, Hull) and Aquacel Ag (ConvaTec, Ickenham) were tried but the patient found a simple adhesive foam dressing most acceptable.

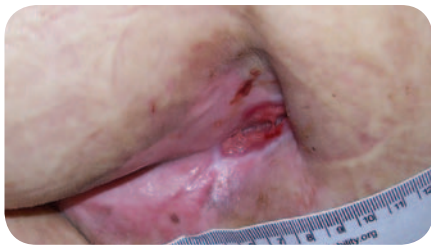
Cutimed Sorbact was applied to the leg ulcer with the primary aim of reducing bioburden and slough and promoting healing. A foam dressing was used as a secondary dressing. After four weeks,



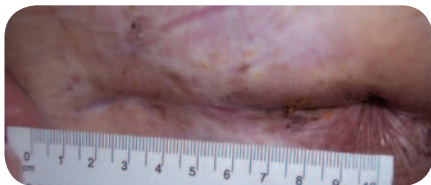
**Figure 9.** The same wound after an extended period of treatment with Cutimed Sorbact. The wound is now covered with 62% epithelial tissue.



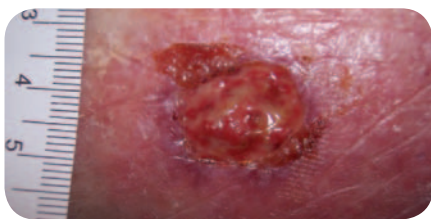
**Figure 10.** A colonised pressure ulcer that refused to heal.



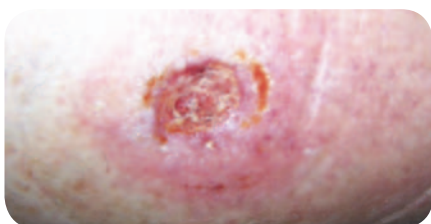
**Figure 11.** The same wound at the end of the 28-day study period.



**Figure 12.** After extended usage of Cutimed Sorbact the wound is fully healed.



**Figure 13.** A small trauma wound which had remained unhealed for three months.



**Figure 14.** The same wound four weeks later. The wound bed is clean and prepared for healing.

significant changes had occurred with the wound bed consisting of 60% slough and 40% granulation tissue. The use of Cutimed Sorbact was continued beyond the four-week study period and after seven weeks the results were remarkably improved, with the wound covered with 62% epithelial tissue (Figure 9). This tissue was pale in colour, probably due to Patient B's physical condition. However, it did not appear to be delaying the wound from healing and did not cause concern.

#### A grade 4 pressure ulcer

Patient C was a 90-year-old male resident of a nursing home. He was immobile and spent most of his time on a dynamic air mattress and cushion. He was a non-smoker with a good diet and was slightly overweight with a BMI of 27. He had a grade 4 pressure ulcer which had developed over his left ischial tuberosity six months previously.

On presentation, the wound consisted of 25% necrotic tissue in the wound base and 75% red but unhealing tissue on the sides of the cavity. There were high levels of haemoserous, extremely malodorous exudate with maceration of the surrounding tissue. The wound measured 2 x 5cm with a depth of 2.5cm (Figure 10), but the patient gave a pain rating of 0 (no pain experienced). Wound management objectives were to debride the necrotic tissue, manage the exudate and promote granulation tissue.

The wound was dressed with a Cutimed Sorbact pad and held in place by a film dressing. After one week of treatment, the necrotic tissue was replaced with yellow slough that covered 25% of the wound bed. The dressing was changed every three days and on day 28 the wound bed contained 100% granulation tissue, the surrounding skin was healthy and there was evidence of epithelialisation at the wound margins. The wound now produced a low amount of serous exudate but some odour remained. The odour finally resolved by week 5. The wound measured 1 x 3cm and the depth had significantly decreased (Figure 11). As a result of the wound's progress, it was decided to continue using the dressings until full healing was achieved at week 18 (Figure 12). The

results of this case study led the nursing home to use Cutimed Sorbact for other patients with suitable wounds.

#### Treatment of a leg ulcer caused by trauma

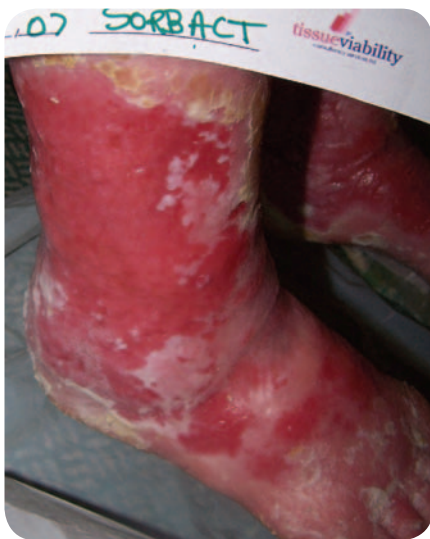Patient D lived with her husband and was a very active 82-year-old with a full social life and an intolerant attitude to any invasion of her lifestyle, which she saw her wound to be. She was overweight with a BMI of 26. After knocking her leg three months previously she developed a leg ulcer that appeared to be enlarging. The wound was considered to have an increased bacterial load due to the presence of malodour and its red and shiny appearance, but there were no signs of infection. A Cutimed Sorbact swab was used on the wound which measured 1.5 x 1.5cm (Figure 13). After five days of treatment the wound measured 3 x 2.6cm due to the debridement of necrotic tissue beneath the surface of the wound. Patient D had an outer ring of induration at the wound margins but this was not thought to be a clinical infection as she did not have a temperature and the wound did not display obvious cellulitis.

After nine days, the wound had debrided and granulation buds were appearing. Within four weeks the wound had fully cleaned and granulation was very apparent with some contraction of the wound margins (Figure 14). The wound went on to heal successfully.

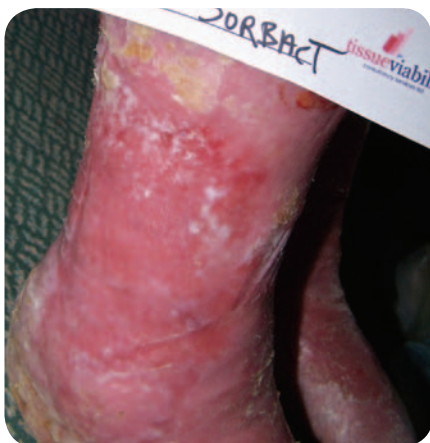#### Treatment of bilateral leg ulcers

Patient E had suffered with bilateral leg ulcers for many years. She had a history of ischaemic heart disease and osteoporosis causing difficulties with mobility. However, she did not take any medication and reported feeling very well. She had been having compression therapy applied for some months. This case study describes the progress of her second leg ulcer (Figure 15), which had been inflamed and wet for many years.

Cutimed Sorbact was applied with the primary aim of reducing bacterial burden and to provide an ideal wound healing environment. After a week the skin appeared to increase in wetness and the presence of blue/green exudate and malodour indicated *Pseudomonas* colonisation. After two weeks of treatment,



**Figure 15.** This patient had suffered with an inflamed and weeping wound for many years. The wound was superficial, painful and covered most of her lower limb.



**Figure 16.** The wound following two weeks of treatment. The changes are very apparent; the reddened area is now paler pink and areas of epithelial tissue are present.

stretches of epithelial tissue were noted and the redness had subsided (Figure 16).

Although this was not the most successfully healed wound, the use of Cutimed Sorbact did progress the wound towards healing, possibly by reducing the quantity of *Pseudomonas* present in the wound.

### Discussion

This was a simple product evaluation which followed the progress of 21 wounds treated with Cutimed Sorbact. No firm conclusions can be drawn from the results due to the small sample size. Nevertheless, an evaluation of

'real life' wounds can be of value to the practitioner who wishes to learn about products and their range of use.

The outcomes of this evaluation demonstrated that Cutimed Sorbact:

- ▶ Progressed over 60% of non-healing wounds to healing
- ▶ Healed or almost healed (e.g. the wound contained granulation or epithelial tissue) 29% of the wounds by day 28
- ▶ Lowered wound pH in 64% of wounds
- ▶ Reduced odour in 58% of patients and eliminated extreme malodour in all wounds
- ▶ Reduced exudate levels in all wounds
- ▶ Improved the condition of the peri-wound area in 30% of patients.

### Conclusion

Cutimed Sorbact has been demonstrated in this series of evaluations to be effective in the treatment and management of many different wound types such as leg ulcers, pressure ulcers, and a post-surgical wound. The product range is unique with a highly effective mode of action and the ability to kick-start the healing process of previously non-healing wounds. The dressings are also a fraction of the cost of some of the silver antimicrobial alternatives. This clinical- and cost-effectiveness makes them well worth considering for both non-healing wounds across a number of indications, and those wounds that have recently formed where there is a risk of infection. **WUK**

### References

- Brett DW (2005) Bacterial resistance to silver in wound care. *J Hosp Infect* 60(1): 1–7
- Cutting K, White R, Edmonds M (2007) The safety and efficacy of dressings with silver - addressing clinical concerns. *Int Wound J* 4(2): 177–84
- Dahlerup J (1989) Drug information. Sorbact: a bacteria-adsorbing compounds. *Sygeplejersken* 89(19): 22
- Edwards L (2001) Colonisation versus infection of indolent venous leg ulcers. *J Comm Nurs* 15(6): 34–6
- Flanagan M (1997) *Wound Management*. Churchill Livingstone, Edinburgh
- Gray D, White R, Kingsley A, Cooper P (2004) Using the Wound Healing Continuum to identify treatment objectives. In: *Applied Wound Management supplement: Part 2 Implementation*. Wounds UK, Aberdeen

Jones SA, Bowler PG, Walker M, Parsons D (2004) Controlling wound bioburden with a novel silver-containing Hydrofiber dressing. *Wound Rep Regen* 12(3): 288–94

Hampton S, Collins F (2003) *Tissue Viability. A Comprehensive Guide*. Whurr Publications, London

MCaffery M, Beebe A (1989) *Pain: Clinical Manual for Nursing Practice*. Mosby Co, St Louis

Meberg A, Schøyen R (1990) Hydrophobic material in routine umbilical cord care and prevention of infections in newborn infants. *Scand J Infect Dis* 22(6): 729–33

Queen D, Orsted H, Sanada H, Sussman G (2004) A dressing history. *Int Wound J* 1(1): 59–77

Tomaselli N, Doughty D (2006) The role of topical silver preparations in wound healing. *J Wound Ostomy Continence Nurs* 33(4): 367–78

Wilson IAI, Henry M, Quill RD, Byrne PJ (1979) The pH of varicose ulcer surfaces and its relationship to healing. *VASA* 8: 339–42

### Key Points

- ▶ An increase in the availability of antimicrobial dressings has led to the overuse of these products, particularly dressings containing silver.
- ▶ The over use of silver dressings has raised concerns over issues such as toxicity, efficacy, bacterial resistance and cost-effectiveness.
- ▶ The Cutimed® Sorbact® range of antimicrobial dressings have a unique mode of action that effectively removes microbes from the wound bed.
- ▶ In a small evaluation, the Cutimed Sorbact dressings were found to be effective at promoting wound healing in 21 patients with non-healing wounds.
- ▶ The Cutimed Sorbact range is a good alternative to other antimicrobial dressings available, without the cost-effectiveness and resistance issues.